

Role Of Reverse Sural Artery Flap In Ankle, Foot And Leg Defects

Dr.N.Ramyadeepthi, M.S, M.Ch¹, Dr.M.Manjula Bai, M.S,M.Ch².

¹Assistant Professor of Plastic Surgery, Kurnool Medical College, Kurnool, Andhra Pradesh, India.

Cell: 919493837522

²I/C Professor of Plastic Surgery, Kurnool Medical College, Kurnool, Andhra Pradesh, India.

Cell : 919440355055

Abstract: To study versatility and feasibility, as well as dimensions of "Reverse sural artery flap" that can be harvested for the defects of lower leg, ankle and dorsum of foot and heel defects.

Keywords: Reverse sural artery flap, For leg foot and ankle defects, Versatility of flap.

I. Introduction

Reconstruction of compound defects of lower third leg, foot and ankle is challenging, due to limited soft tissue availability and lack of muscle bellies in that region. Various reconstructive options like local fasciocutaneous flaps, cross leg flaps and more recently with introduction of free flaps, the problem can be dealt with maximum possible extent, but all have their own advantages and disadvantages. Free flaps demand manpower, technically demanding, expensive and need prolonged intra operative time and intense post-operative care.

"REVERSE SURAL ARTERY FLAP" was introduced as a reasonably very good solution for addressal of such defects as a alternative to free flaps, with qualities like reliability ,ease of dissection, fixed perforator ,short operating time, requiring less manpower and with the inclusion of sural nerve in the flap serves as a sensate flap especially for heel defects. So the study of role, versatility, dimensions, feasibility of flap in leg, ankle and foot defects is analyzed in our study.

II. Materials And Methods

This is a retrospective study of "Reconstruction of lower leg and foot defects with sural artery flap" on 15 patients irrespective of sex and age between 5-70 years of age during August 2012 - July2015. Duration of study 3 years.

Operative Technique: After identifying major perforator of lateral side of leg, flap is marked according to dimensions of true defect, flap elevated in sub fascial plane and the three imp structures like short saphenous vein, sural nerve and sural artery were included and perforators preserved and flap transferred to the defects and inset given, donor site of flap was grafted with split thickness skin graft and dressing done. All operative procedures were done under spinal anesthesia and minor procedures like delay were done under local anesthesia.

III. Surgical Anatomy

"Reverse sural artery flap" is an axial flap based on vascular plexus around the sural nerve formed by anastomosis between peroneal artery perforators located at 5 cm and 10 cm from tip of lateral malleolus and median sural artery , branch of popliteal artery.

The median sural artery takes its origin from popliteal artery at the level of knee joint and runs downwards two-three cm before joining the median sural nerve descending between two heads of gastrocnemius muscle. The artery courses along the side of sural nerve to the distal third of leg and terminates by anastomosing with supra malleolar branch of peroneal artery. Usually two paired vene commitantes travel with median sural artery (Fig-1).

Approximately four-eight (4-8) fasciocutaneous perforators from peroneal artery and vene commitantes follow the course of posterior intermuscular septum to supply crural fascia. This plexus extends from posterior margin of lateral malleolus to the superior part of leg. They also inter-communicate with axial pattern arteries that accompany the median sural cutaneous nerve .These perforators typically located at five (5) cm and ten (10) cm from tip of lateral malleolus.

Sural nerve is a sensory nerve supplying the skin of postero lateral aspect of leg and foot. It is formed by the union of medial sural cutaneous nerve (MSCN), a branch of tibial nerve and lateral sural cutaneous nerve

(LSCN), branch of common peroneal nerve. Both unite to form sural nerve, but the site of union of these two nerves is highly variable (Fig-1).

It may be in popliteal fossa or in distal third of leg or at ankle joint. Approximately at midpoint of leg medial sural cutaneous nerve and medial sural artery form a nerve-artery complex in suprafascial plane and is accompanied by short saphenous vein.

The short saphenous vein takes its origin from lateral extension of dorsal venous arch of foot, lies in supra fascial plane, it passes posteriorly behind the lateral malleolus along with sural nerve in suprafascial plane upto midpoint of leg, after which it becomes subfascial and travel upwards in subfascial plane in midline between two heads of gastrocnemius muscle, at popliteal fossa it drains into popliteal vein. It is flanked by its accompanying arteries, which also contribute to the vascular plexus of the flap (Fig-1).

The venous drainage of flap is by concomitant veins of accompanying arteries of short saphenous vein.

These small veins are anastomosed to short saphenous vein in some places and play a role in bypassing the valves of saphenous vein.

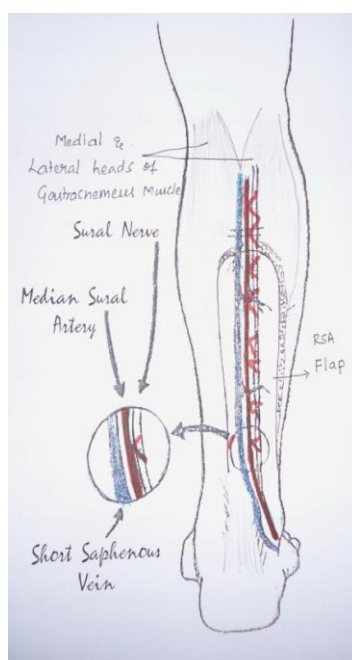


Figure-1: Flap marking

IV. Results And Observations

1. Fifteen (15) cases were performed in our department over a period of three (3) years from August 2012 to July 2013.
2. Patient age in our study ranged from (5- 70) five years to seventy years, with a mean age of thirty seven (7) years. Ten (10) male patients and five (5) female patients underwent “REVERSE SURAL ARTERY FLAP” in this series with male to female ratio of (2: 1) two: one.
3. Trauma following road traffic accident was the most common etiological factor requiring flap cover in our study. One case of post burn chronic non healing ulcer, one case of post traumatic chronic non healing ulcer, two cases were defects after excision of malignancies.
4. Defects around ankle, foot (6) and dorsum of foot (6) were equal in incidence. The other sites include lower third leg.
5. Structures exposed at the defect site in various cases are Tibia, Fibula, Calcaneum, Tarsal and metatarsals, medial and lateral malleoli, tendoachillis and extensor tendons.
6. Co-morbid conditions in our study were smoking. Nine patients were chronic smokers in our study.
7. Interval between injury and flap cover ranged from three (3) days to two (2) years.
8. Pre - op Doppler was done to study peroneal septocutaneous perforators in all cases. Tourniquet was used routinely. Pivot point of all the flaps raised was five- seven cms above the lateral malleolus. In our study, the level of flap elevation in three (3) cases, reached upper one- third of the leg contrary to the conventional limit of lower third. Donor site of flap and under surface of flap over bridging segment of the flap were covered with split skin thickness graft.
9. Flap dimensions ranged from a minimum of eighteen x five (18x5) to thirty x nine (30x9) cms and the dimensions of island flap elevated were seven x five (7x5) cms and seven x six (7x6) cms.

10. In our study all flaps were transferred to the defect site as interpolation flaps. The pedicles were divided at three weeks to four months duration and bridging segment was returned to the Donor site, except in two (2) cases where island flap was done. Pre-operative Flap delay was done in three (3) cases.
11. In our study, flap necrosis was found in five cases. Among them three cases had full thickness flap necrosis, which were debrided and re inset was given. One flap had eight (8) cms of flap loss and flap was debrided and returned to Donor site .Remaining two cases had only marginal epithelial necrosis and those were managed conservatively.
12. Venous congestion was identified to be the most common cause of flap necrosis.
13. Donor site morbidity was minimal except for scarring at the donor site. None our patients complained of lateral foot hypoesthesia or painful neuromas following sacrifice of sural nerve.
14. During follow up period no flap or no donor site complications were noted.

V. Discussion

Fachinelli first reported the anatomy of superficial sural artery in 1981[1], in the same year Ponten introduced the concept of fasciocutaneous flap in lower limb[2]. In 1983 Donski and Fogdestam, described reverse flow in reverse sural artery fasciocutaneous flap based on peronealartery perforator[3]. In 1992 Masquelet et al described the concept of sural neurocutaneous flap[4]. In 1994, Hasegawa refined the technique and proposed new terminology for the flap[5]. In 1999, Nakajima and Imanishi described arterial anatomy and venous drainage of reverse sural artery flap[6]. In 2001, Le Fourn in 2001 introduced the concept of distally based sural artery fasciomuscular flap including part of gastrocnemius muscle in the flap[7].

In our study irrespective of donar defect quality, reverse sural artery flap is a reasonably a very good choice, if there is a perforator reliability and preservation of arterial plexus around the sural nerve and with fine surgical technique and a good post operative care resulted in a very good outcome.

In our study, among the two island flaps one has superficial marginal necrosis of one centimeter which was managed conservatively and the remaining has very good outcome (Fig-3).

Out of 15 cases prior surgical delay was given to 3 cases in 1:1 ratio with a very good outcome without any complications.

The common complication, we encountered during post operative period was marginal flap necrosis due to venous congestion. Out of 15 cases, 20% of the cases (3 cases) had 1-1.5 cms of full thickness flap necrosis and of cases had only epithelial necrosis. We managed full thickness flap loss by doing debridement and re inset of the flap after two weeks of flap elevation. Epithelial necrosis was managed conservatively with dressings. In one case (1), 6.6% we had eight (8)cms of full thickness flap loss by third post operative day. So flap was debrided and returned to the donor site. The reason for such an extensive flap loss was damage to the short saphenous vein during flap elevation led to severe post operative venous congestion and flap loss inspite of post operative care.

Another complication was wound dehiscence found in five (33.34%) cases, but it was localized so managed conservatively with dressings. The reason for flap dehiscence was flap necrosis, scarred margins of defects due to chronicity and old age. But in all cases we could cover the critical area without any further complications. But 3(20%) cases were debrided and re inset was done due to full thickness flap loss.

NAKAYAMA et al in 1999, reported in their cadaveric studies the probable mechanism of venous drainage of "Reverse sural artery flap" via circuitous bypass between the venae comitantes of accompanying arteries of short saphenous vein and short saphenous vein [6].

In our study, flap complication rate of thirty three 33.33% (5 out of 15 cases had flap necrosis) was noted. Venous congestion was the main draw back in these flaps because of unsatisfactory venous drainage .Presence of valves in the short saphenous vein prevents retrograde blood flow leading to continuous ingress to the flap without egress. Venous hypertension could thus propagate and hinder normal venous drainage through valve less small veins with the flap.

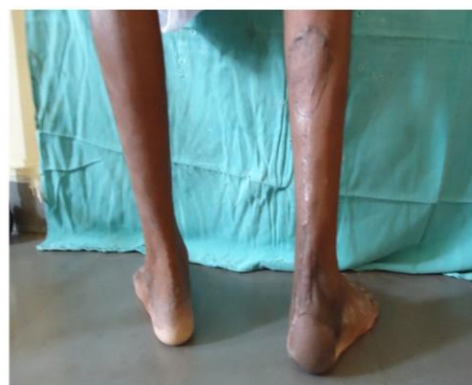
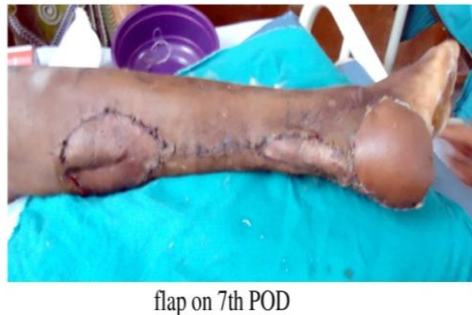
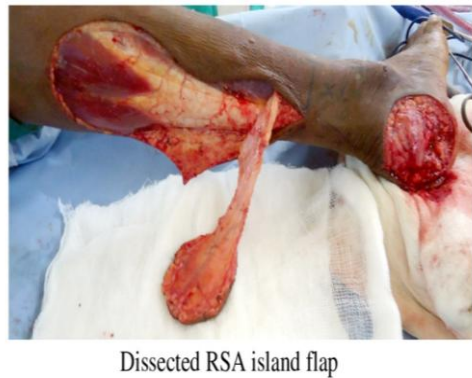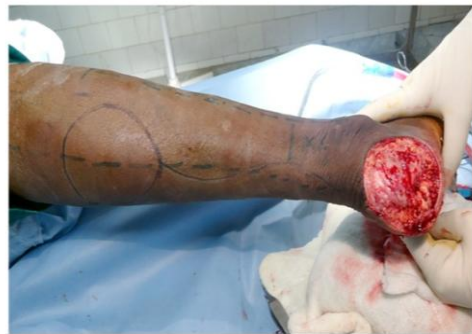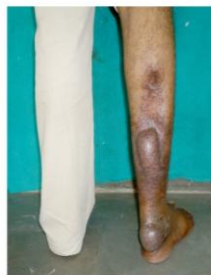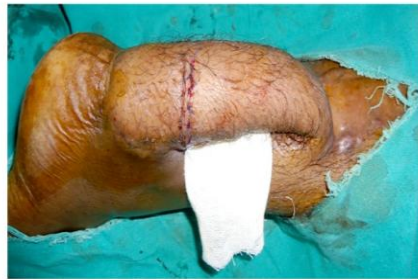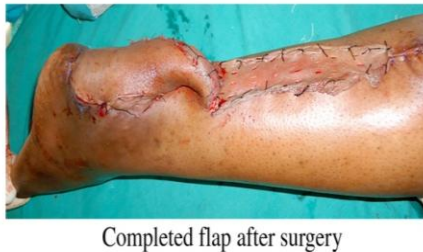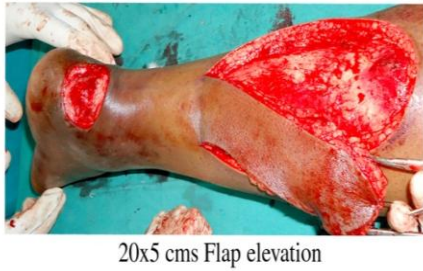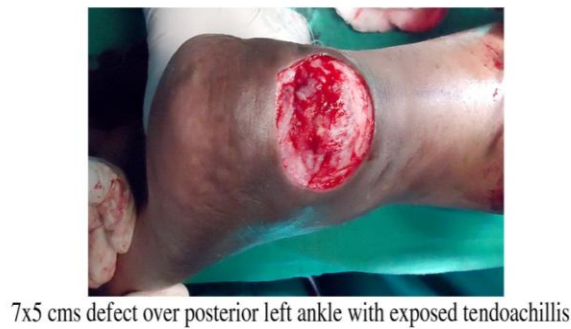Figure -2: Pedicled reverse sural artery flap.

Figure -3: Island reverse sural artery flap

VI. Conclusions

“Revere sural artery flap” is a good option for lower third leg, foot and ankle defects by virtue of its reliable blood supply, short operating time, minimal equipment, easy to execute under regional anesthesia with minimal blood loss and without sacrificing any major vessel. Reliability of “Reverse sural artety flap” is well established when used for soft tissue reconstruction of moderate defects and reconstruction of moderate defects

and restriction of flap elevation to two third of the leg. Extension of flap elevation to upper third of leg by doing prior delay has not increased complication rates and increased the flap dimensions for larger defects. Cases for which early flap cover was given are very good with no flap necrosis. Donor site morbidity is minimal except for scarring in the region.

References

- [1] *Fachinelli A et al* The Vascularised SuralNerve :Anatomy and Surgical Approach Int J Microsurg1981 ; 3: 57.
- [2] *Ponten B* The fasciocutaneousflap : Its use in soft tissue defects of the lower leg Br J PlastSurg1981 ; 34 :215 -220.
- [3] *Donski PK et al* Distally based fasciocutaneous flap from the suralregion :A preliminary report Scan J ReconstrSurg 1983; 17: 191 - 196.
- [4] *Masquelet AC et al*.Skin Island flaps supplied by the vascular axis of the sensitive superficial nerves: Anatomic study and clinical experience in leg Plastreconstructive surg -1992; 89:1115 – 21.
- [5] *Hasegawa M et al* The distally based superficial sural artery flap PlastReconstrSurg 1994 ; 93:1012 -1020.
- [6] *Nakajima H et al* Accompanying Arteries of the Lesser Saphenous Vein and Sural Nerve .Anatomic Study and its Clinical Applications. PlastReconstrSurg1999 ; 103 :104 -120.
- [7] *Le Fourn B et al* Diatally Based Sural FasciomuscularFlap: Anatomic Study and Application For Filling Leg or Foot Defects PlastReconstrSurg2001; 107: 67 – 72.